

# 49,XXXXY Syndrome with Hydronephrosis Caused by Intravesical Ureterocele

Yoshiyuki Kojima Yutaro Hayashi Tetsuji Maruyama Shoichi Sasaki  
Tohru Mogami Kenjiro Kohri

Department of Urology, Nagoya City University Medical School, Nagoya, Japan

## Key Words

49,XXXXY syndrome · Hydronephrosis · Ureterocele

## Abstract

A 1-month-old boy was referred to our hospital with right hydronephrosis. Excretory urography showed poor visualization of the right kidney and a filling defect in the bladder. Chromosomal analysis of peripheral blood revealed a karyotype of 49,XXXXY, and a diagnosis of 49,XXXXY Klinefelter's syndrome associated with hydronephrosis caused by intravesical ureterocele was made. 49,XXXXY Klinefelter's syndrome with anomalies of the urinary tract is extremely rare, and only 2 cases have been reported so far.

Copyright © 2000 S. Karger AG, Basel

## Introduction

49,XXXXY syndrome represents a rare sex chromosome aneuploidy. The classic clinical findings reported in persons with this karyotype included radioulnar synostosis, mental deficiency, and hypogonadism [1–5]. Various anomalies have been reported in this syndrome [5–9]. However, urinary tract malformations are extremely rare

and only 2 cases have been reported previously [10]. We report 49,XXXXY syndrome in a 1-month-old boy with hydronephrosis caused by intravesical ureterocele.

## Case Report

A 1-month-old boy was referred to our hospital with right hydronephrosis detected during examination for the cause of urinary tract infection. His mother had smoked 20 cigarettes/day during pregnancy. He was born by cesarean section at 43 weeks of gestation and weighed 2,620 g. He presented with a characteristic facial appearance with quadrangular head shape. On physical examination left cryptorchidism was observed, but the penis and testes were almost normal in size. Chromosomal analysis of the peripheral blood with 50 cells showed 49,XXXXY (fig. 1). Endocrine functional values were within normal limits. Ultrasonography was suggestive of right hydronephrosis and a swelling on the right side of the bladder. Excretory urography showed poor visualization of the right kidney and a filling defect in the bladder (fig. 2). The diagnosis of 49,XXXXY Klinefelter's syndrome with unilateral cryptorchidism and hydronephrosis caused by intravesical ureterocele was made, and orchiopexy and transurethral incision of ureterocele were performed. After endoscopic incision, adequate decompression of the ureterocele was obtained and hydronephrosis decreased. However, since postoperative voiding cystourethrography demonstrated the presence of vesicoureteral reflux, excision of the ureterocele and ureteral reimplantation were performed. The patient remains in good general condition, but mental retardation has been detected.

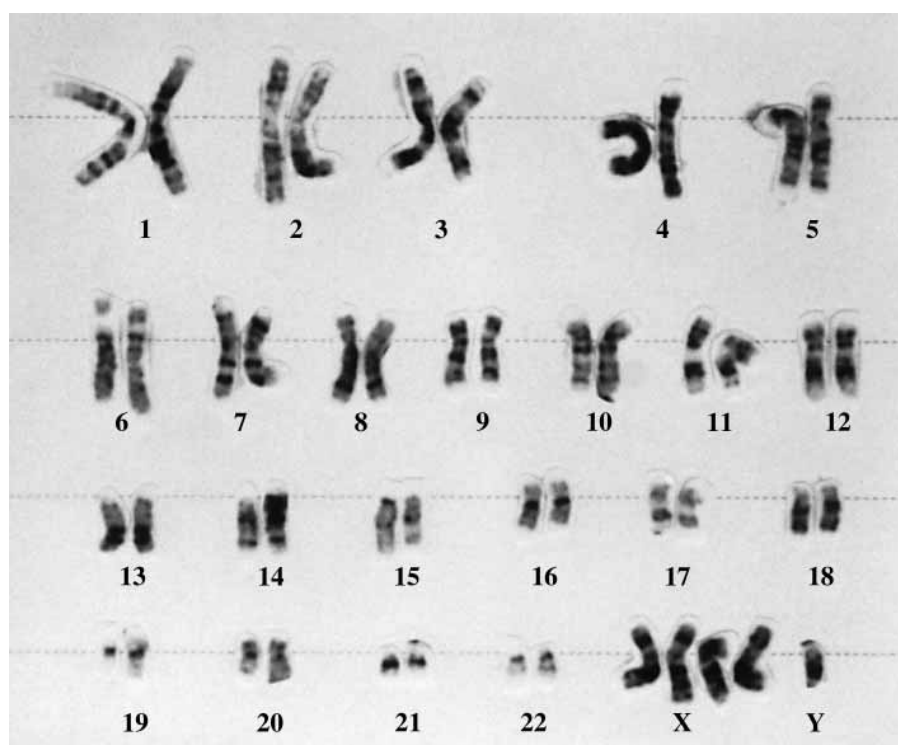
## KARGER

Fax + 41 61 306 12 34  
E-Mail karger@karger.ch  
www.karger.com

© 2000 S. Karger AG, Basel  
0042–1138/99/0633–0212\$17.50/0

Accessible online at:  
www.karger.com/journals/uin

Yoshiyuki Kojima, MD  
Department of Urology, Nagoya City University Medical School  
1, Kawasumi, Mizuho-cho  
Mizuho-ku, Nagoya 467-8601 (Japan)  
Tel. +81 52 853 8266, Fax +81 52 852 3179

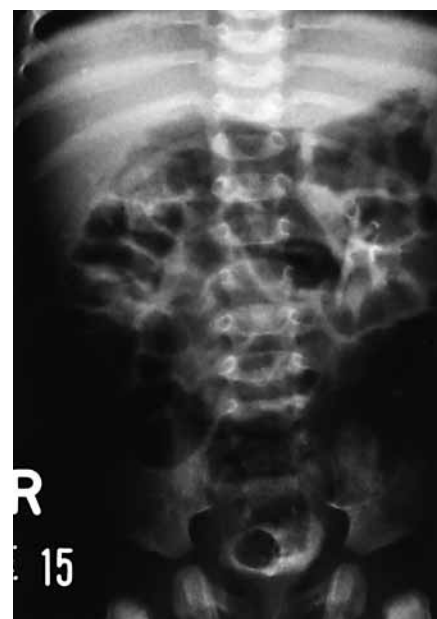

**Fig. 1.** Chromosome analysis reveals a karyotype of 49,XXXXY.

## Discussion

Karyotype 49,XXXXY, which is the most severe variant, is a rare form of Klinefelter's syndrome. Since the initial report of 49,XXXXY karyotype nearly 40 years ago [1], over 100 cases have been reported in the world literature [4, 5, 8]. A 49,XXXXY karyotype is thought to arise from maternal non-disjunction during both meiosis I and meiosis II [11–14]. Such successive non-disjunction theoretically produces an egg with four X chromosomes which, when fertilized by a Y-bearing sperm, results in an embryo with 49,XXXXY syndrome [11, 14]. Characteristic features include coarse facies, skeletal anomalies, hypogonadism, and mental retardation [1–5]. Various anomalies including cleft palate [6], congenital heart disease (patent ductus arteriosus, atrial and ventricular septal defect, tetralogy of Fallot, and so on) [5, 7], and external genital abnormalities (cryptorchidism, bifid scrotum, ambiguous genitalia, and so on) [8, 9] have been reported in this variant of Klinefelter's syndrome.

Klinefelter's syndrome with anomalies of the urinary tract is extremely rare. Egli and Stalder [10] reported only one renal anomaly (cystic kidney) in 276 cases of 47,XXY syndrome, and no renal anomalies in 7 cases of 48,XXXXY



**Fig. 2.** Excretory urography shows poor visualization of the right kidney and a filling defect in the bladder.

syndrome. In 17 cases of 49,XXXXY syndrome, urinary tract malformations were found in 2 patients: both had hydronephrosis, which was associated with ureterocele in 1 patient [10]. Our patient is the second case that we have encountered in which Klinefelter's syndrome was associ-

ated with hydronephrosis caused by ureterocele. Since urinary tract malformations seem to occur only occasionally in 49,XXXXY Klinefelter's syndrome, a direct correlation of ureterocele with this syndrome is inconclusive.

References

1 Fraccaro M, Kaijser K, Lindsten G: A child with 49,XXXXY syndromes. *Lancet* 1960;ii: 899-902.

2 Singh TH, Rajkova S: 49,XXXXY chromosome anomaly: An unusual variant of Klinefelter's syndrome. *Br J Psychiatry* 1986;148: 209-210.

3 Kleczkowska A, Fryns JP, Van den Berge: X-chromosome polysomy in the male. The Leuven experience 1966-1987. *Hum Genet* 1988; 80:16-22.

4 Linden MG, Bender BG, Robinson A: Sex chromosome tetrasomy and pentasomy. *Pediatrics* 1995;96:672-682.

5 Peet J, Weaver DD, Vance GH: 49,XXXXY: A distinct phenotype. Three new cases and review. *J Med Genet* 1998;35:420-424.

6 Velidedeoglu HV, Demir Z, Coskunfirat OK, Kurtay A: Uncommon Klinefelter's variant (49,XXXXY) with cleft palate. *Ann Plast Surg* 1997;39:213-215.

7 Karsh RB, Knapp RF, Nora JJ, Wolfe RR, Robinson A: Congenital heart disease in 49,XXXXY syndrome. *Pediatrics* 1975;56: 462-464.

8 Sheridan MK, Randlinski SS, Kennedy MD: Developmental outcome in 49,XXXXY Klinefelter syndrome. *Dev Med Child Neurol* 1990; 32:532-539.

9 Hecht F: Observations on the natural history of 49,XXXXY individuals. *Am J Med Genet* 1982;13:335-336.

10 Egli F, Stalder G: Malformations of kidney and urinary tract in common chromosomal aberrations. *Hum Genet* 1973;18:1-15.

11 Villamar M, Benitez J, Fernandez E, Ayuso C, Ramos C: Parental origin of chromosomal non-disjunction in a 49,XXXXY male using recombinant-DNA techniques. *Clin Genet* 1989;36: 152-155.

12 Deng HX, Abe K, Kondo I: Parental origin and mechanism of formation of polysomy X: An XXXXX case and four XXXXY cases determined with RFLPs. *Hum Genet* 1991;86:541-544.

13 Huang THM, Greenberg F, Ledbetter DH: Determination of the origin of non-disjunction in a 49,XXXXY male using hypervariable dinucleotide repeat sequences. *Hum Genet* 1991; 86:619-620.

14 Leal CA, Belmont JW, Nachtman R, Cantu JM, Medina C: Parental origin of the extra chromosomes in polysomy X. *Hum Genet* 1994;94:423-426.